



TMOD EXAMINATION: SAMPLE CASE 1

Demographics

42-year-old white female; computer programmer

Chief complaint

red eye

History of present illness

Character/signs/symptoms: redness worse in the inner corner

Location: OD

Severity: moderate, getting worse

Nature of onset: sudden

Duration: 2 days

Frequency: constant

Exacerbations/remissions: none

Relationship to activity or function: none

Accompanying signs/symptoms: mild discomfort, slight tearing

Secondary complaints/symptoms

none

Patient ocular history

last comprehensive eye exam 1 year ago; wears PALs

Family ocular history

mother: cataract surgery at age 55

Patient medical history

inflammatory bowel disease diagnosed 5 years ago

Medications used by patient

artificial tears q.i.d. for the past 2 days; oral prednisone; ibuprofen; multivitamin

Patient allergy history

dust; pollen; NKDA

Family medical history

mother: type 2 diabetes mellitus

Review of systems

Constitutional/general health: occasional malaise

Ear/nose/throat: denies

Cardiovascular: denies

Pulmonary: denies

Dermatological: denies

Gastrointestinal: occasional diarrhea with cramping

Genitourinary: denies

Musculoskeletal: denies

Neuropsychiatric: denies

Endocrine: none

Hematologic: none

Immunologic: none

Mental status

Orientation: oriented to time, place, and person

Mood: appropriate

Affect: appropriate

Clinical findings

BVA: Distance

OD: 20/20

OS: 20/20

Pupils: PERRL, negative RAPD

EOMs: full, no restrictions

Confrontation fields: full to finger counting OD, OS

Slit lamp:

lids/lashes/adnexa: unremarkable OD, OS
conjunctiva: see **Image 1 OD**, normal OS
cornea: clear OD, OS
anterior chamber: deep and quiet OD, OS
iris: normal OD, OS
lens: trace NS OD, OS
vitreous: clear OD, OS

IOPs: 24 mmHg OD, 25 mmHg OS @ 9:30 AM by applanation tonometry

Fundus OD:

C/D, macula, posterior pole: see **Image 2**
periphery: unremarkable

Fundus OS:

C/D, macula, posterior pole: see **Image 3**
periphery: unremarkable

Blood pressure: 124/88 mmHg, right arm, sitting

Pulse: 72 bpm, regular

Image 1: OD right gaze

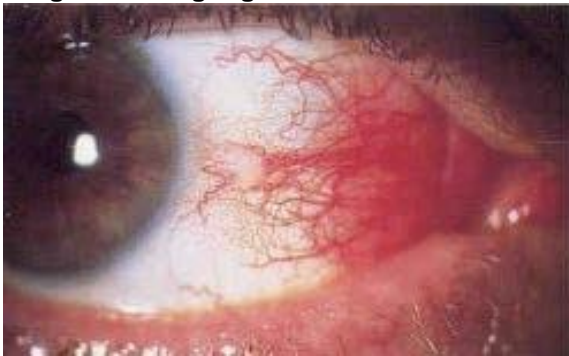

Image 2

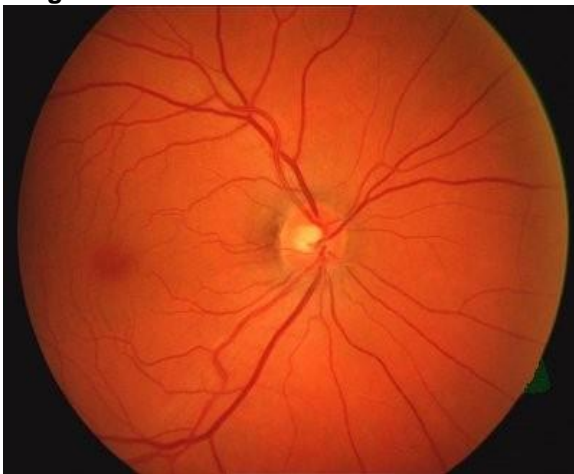
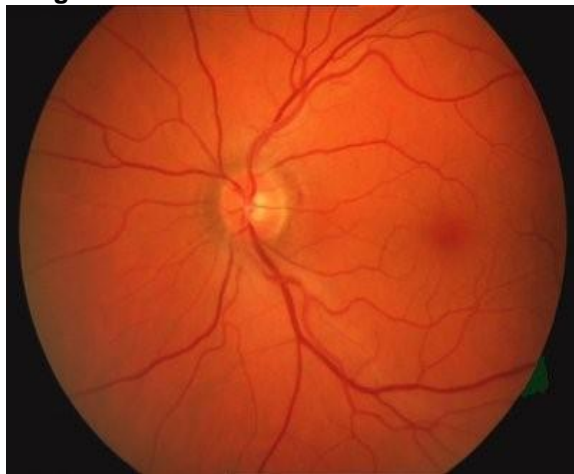


Image 3



correct answer

1. Which of the following is the most likely diagnosis of this patient's anterior segment condition OD? **(Diagnosis)**
 - a. Nodular episcleritis
 - b. Phlyctenular keratoconjunctivitis
 - c. Conjunctival abrasion
 - d. Inflamed pingueculum

2. Which of the following is the most appropriate treatment for this patient's anterior segment condition OD? **(Treatment / Management)**
 - a. Polytrim® solution q.3h
 - b. Natamycin suspension q.4h
 - c. Viroptic® solution q.2h
 - d. Erythromycin ointment b.i.d.
 - e. FML® suspension q.i.d.

3. After initiating treatment, which of the following is the most appropriate follow-up interval? **(Related to Treatment / Management)**
 - a. 24 hours
 - b. 4 days
 - c. 4 weeks
 - d. 3 months
 - e. 6 months
 - f. 1 year

4. Assuming appropriate treatment is initiated, which of the following clinical findings will likely manifest at the next follow-up examination? **(Related to Treatment /Management)**
 - a. Tenderness of the globe to touch
 - b. Elevated intraocular pressure
 - c. Reduced ocular injection
 - d. Corneal melt